

# JIACD Continuing Education

## Successful Management of a Severe Case of Bisphosphonate Related Osteonecrosis of the Jaw in a Multiple Myeloma Patient

Cesar Luchetti, DDS, MS<sup>1</sup> • Sebastian Yantorno, MD<sup>2</sup> • Julian Barrales, MD<sup>3</sup>  
Juan Napal, MD<sup>4</sup> • Jorge Milone, MD, PhD<sup>5</sup> • Alicia Kitrilakis, DDS, PhD<sup>6</sup>

### Abstract

**Background:** Bisphosphonate-related osteonecrosis of the jaw (BRONJ) is a serious oral complication of bisphosphonate treatment involving the exposure of necrotic maxillary or mandibular bone. BRONJ is associated with pain, paresthesia, and oral dysfunction generating an impairment of the quality of life. Treatment of this complication remains difficult and the most useful action is prevention.

**Case Report:** This is a case report of a multiple

myeloma patient whose first signs of BRONJ began in 2002 with the development of an aggressive bilateral osteonecrosis of the mandible. Successful management of this case is described with 17 months of follow up monitoring.

**Conclusions:** This case supports the concept that BRONJ may be successfully treated. The approach described to treat this case, especially regarding sequestrum management, could minimize the surgical corrections after the sequestrum is removed.

**KEY WORDS:** Bisphosphonate necrosis, osteonecrosis, multiple myeloma

1. Associate Professor, Department of Implant Dentistry. National University of La Plata. (Universidad Nacional de La Plata). La Plata, Buenos Aires, Argentina.
2. Specialist in Haematology and Staff of the Bone Marrow Transplant Unit. Italian Hospital of La Plata (Hospital Italiano de La Plata). La Plata, Buenos Aires, Argentina.
3. Specialist in Infectology. La Plata, Buenos Aires, Argentina
4. Specialist in Internal Medicine and Staff of the Bone Marrow Transplant Unit. Italian Hospital of La Plata (Hospital Italiano de La Plata). La Plata, Buenos Aires, Argentina.
5. Specialist in Internal Medicine and Specialist in Haematology. Head of Oncohaematology and Transplants and Director of the Bone Marrow Transplant Unit. Italian Hospital of La Plata (Hospital Italiano de La Plata). La Plata, Buenos Aires, Argentina.
6. Head Professor, Department of Implant Dentistry and Department of Prosthodontics - National University of La Plata. (Universidad Nacional de La Plata) La Plata, Buenos Aires, Argentina

***This article provides 2 hours of continuing education credit.  
Please click here for details and additional information.***

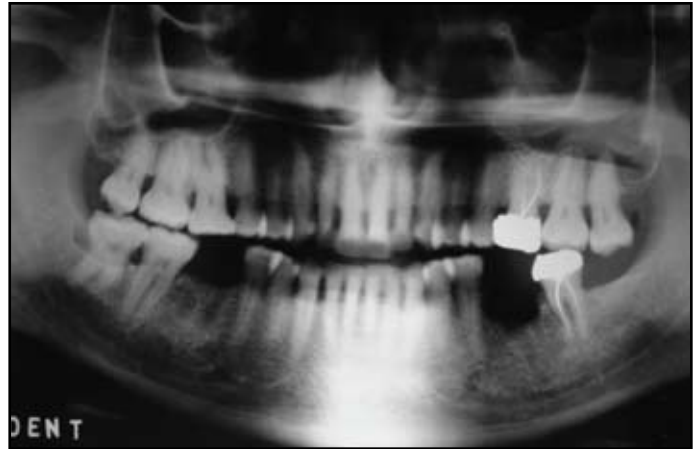
### Learning Objectives

After reading this article, the reader should be able to:

1. Discuss Bisphosphonate Related Osteonecrosis of the Jaw (BRONJ) and its causes.
2. Understand how to diagnosis and manage BRONJ
3. Understand the surgical and pharmacological management of BRONJ

## INTRODUCTION

Bisphosphonates, a class of drugs that inhibit bone resorption, were widely developed over the last four decades starting with the work of Herbert Fleish, who published the first report in 1968.<sup>1</sup> To date, the main use of the drug was for the prevention and treatment of osteoporosis and other bone metabolism diseases, based on their ability to decrease bone turnover through the inhibition of osteoclast differentiation and a decrease in its activity and survival rate.<sup>2</sup> Recently, bisphosphonate use was extended to treat oncological diseases which present bone affection such as multiple myeloma and bone metastasis, in order to lower the skeletal effects. First studies are dated at the beginning of the nineties,<sup>3</sup> being today a very important component of the therapeutic approach in these conditions.<sup>4</sup> However, by the end of 2003, a new and a challenging entity developed as a complication in patients treated with bisphosphonates was described mainly associated with Pamidronate and Zoledronic Acid.<sup>5,6</sup> Bisphosphonate-related osteonecrosis of the jaw (BRONJ) is a serious oral complication of bisphosphonate treatment involving the exposure of necrotic maxillary or mandibular

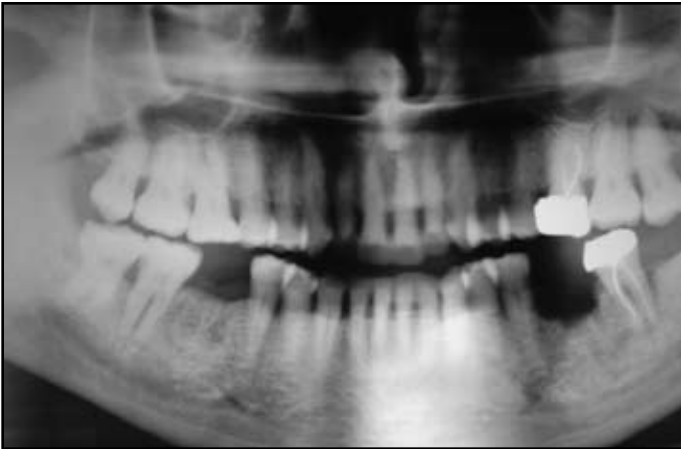


**Figure 1:** Non-healing sockets after extractions in December 2002.

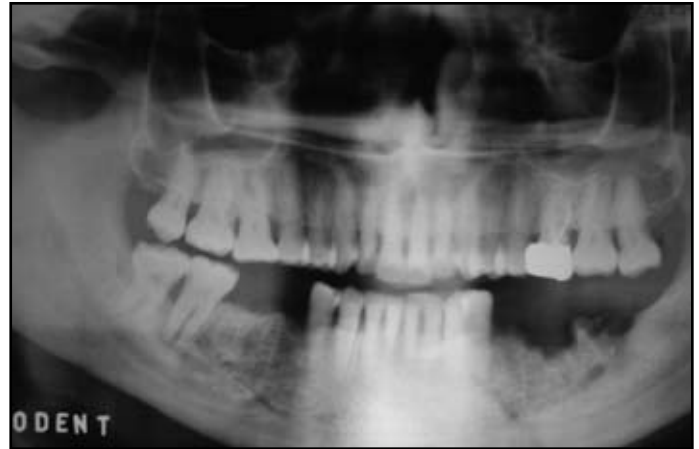bone, occurring in 1.8 to 12.8 % of the cases with intravenous bisphosphonates administration.<sup>7</sup>

## CASE DESCRIPTION

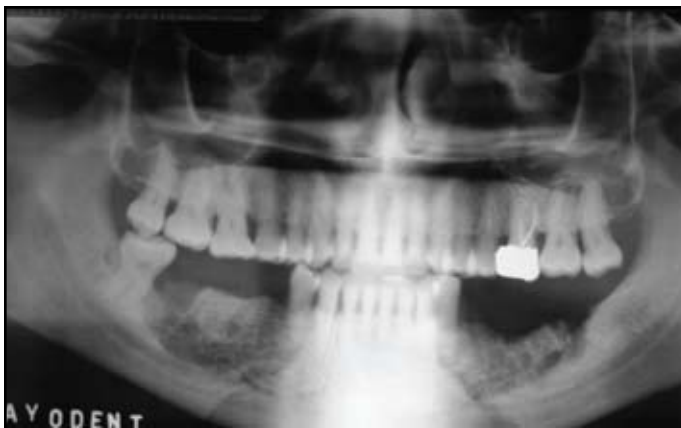A 48 year old white, male patient was referred to the Department of Implant Dentistry at the National University of La Plata. (Universidad Nacional de La Plata) in La Plata, Buenos Aires, Argentina in December 2005. The patient was undergoing treatment for multiple myeloma. The patient was diagnosed with multiple myeloma, IgG monoclonal band in proteinogram, in June 1996. Upon diagnosis of multiple myeloma, the patient was initially treated with four cycles of the "VAD protocol" (vincristine, adriamycin and dexamethasone) and autologous bone marrow transplantation in May 1997. Maintenance was accomplished with interferon until 2000, and later thalidomide until 2002. Concomitant treatments with bisphosphonates were pamidronate from September 2001 to December 2001 and zoledronic acid from January 2002 to December 2005. The patient experienced a relapse in 2006 and bortezomib was used for 8 cycles. The patient has since experi-



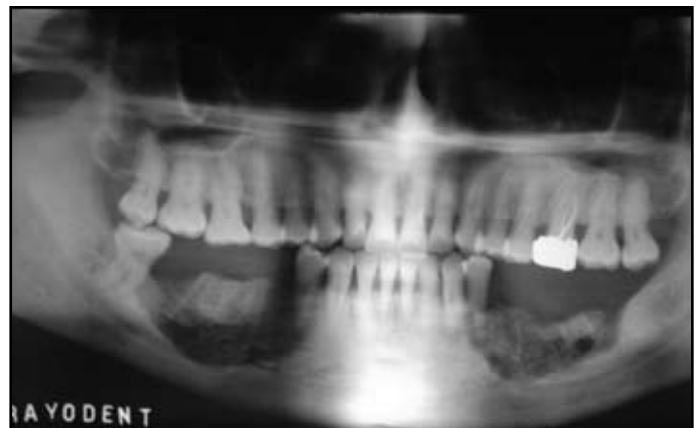**Figure 2:** Control radiograph in March 2003 showed no improvements.



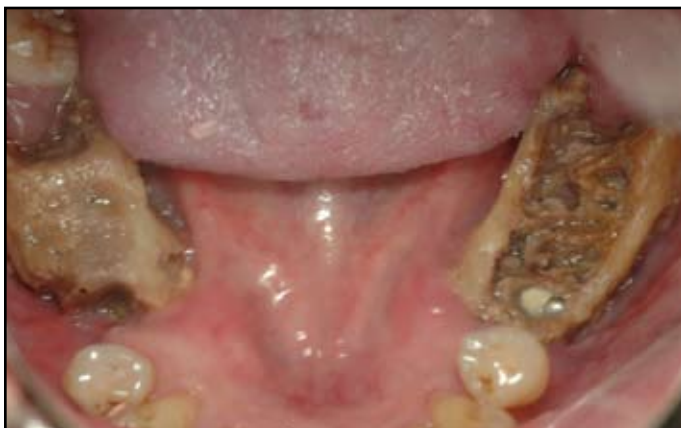**Figure 3:** In September 2003, patient lost teeth 18, 20, and 29.



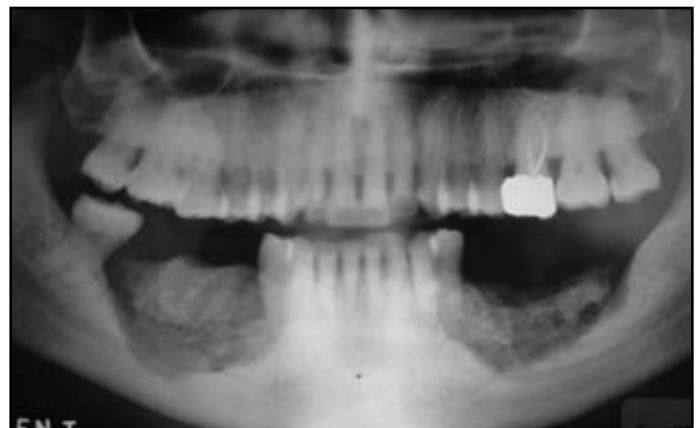**Figure 4:** Patient lost an additional tooth, number 31 in March 2004 and boy sequestrums began to form.



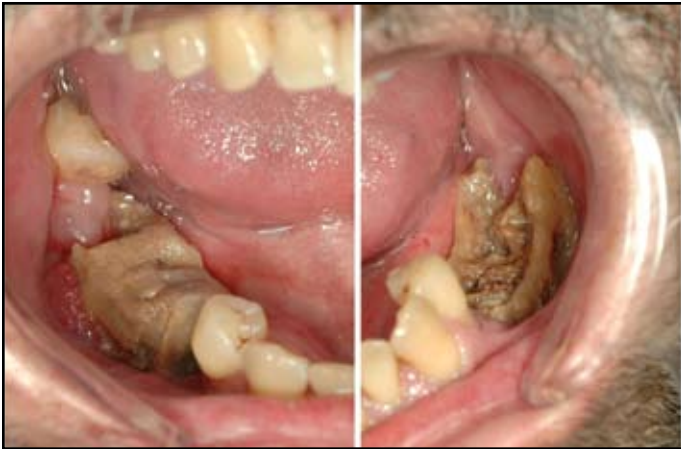**Figure 5:** Control x-ray in December 2004 showed the limits of the affected bone.



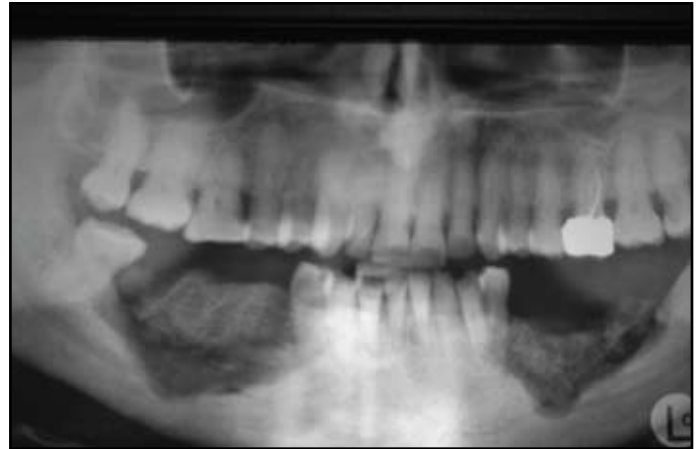**Figure 6:** First contact with the patient in December 2005. Extensive bilateral bone exposure is noted.



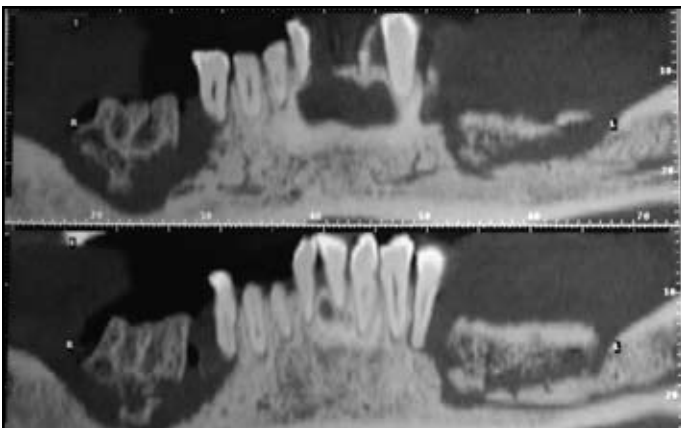
**Figure 7:** Radiograph showing the status of the affected bone in December 2005.



**Figure 8:** Clinical situation in September 2006, without changes.



**Figure 9:** Radiograph taken in November 2006 showing a progression of the affected bone.



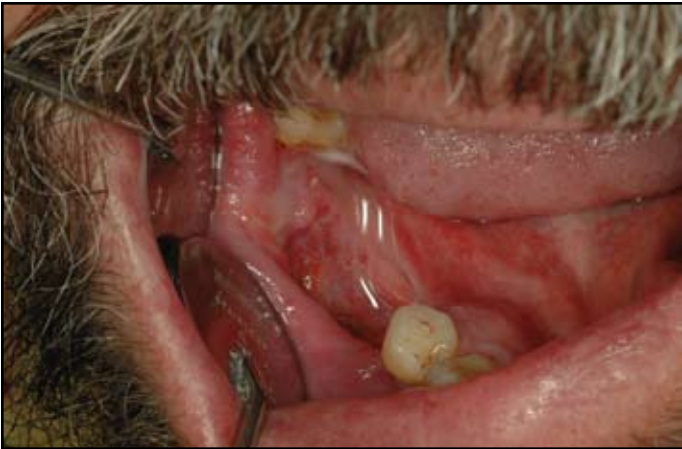**Figure 10:** Computer tomography scan showing the extension of the lesions.

enced complete remission following this treatment.

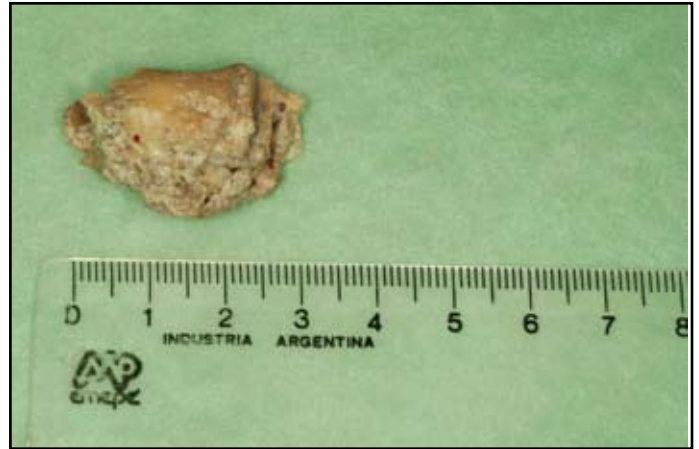In 2002, the patient had some routine dental extractions which never fully healed and resulted in chronically exposed bone. Suspecting myeloma dissemination to the mandible, the oral surgeon at that time took a biopsy sample. The condition now known as BRONJ was not yet known at that time (figure 1). A few months later, the condition became increasingly aggravated, with the consequent loss of more teeth and a progressive affectation to the bone (figures 2-5).

The patient was first seen in our department in December 2005 and presented with significant bilateral bone exposure in the mandible (figures 6,7). According to the recommendations at the time, our approach was to try to maintain the exposed bone as clean as possible to prevent further infection. Our treatment consisted of long term antibiotics (Amoxicillin plus clavulanic acid, 1 gr, twice a day and metronidazole 500 mg twice a day), local rinses with chlorhexidine 0.12 % 3 times a day, and rinses with 3% hydrogen peroxide once a day. After nine months of this conservative treatment, the patient showed no improvement. Additionally, the exposed bone in the right side of the mandible began to form a sequestrum and loosen (figures 8-10). At this time, the patient asked for a solution to his problem. We explained the risks and our approach based in the management of previous smaller cases. Following our discussions of the risk and benefits of treatment, the patient agreed to proceed. As such, our treatment protocol for this patient was modified as follows.

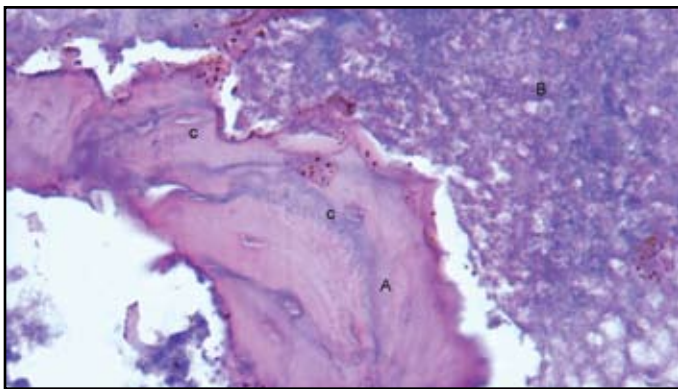
We started to manipulate the bony sequestrum by gently trying to loosen it three times a



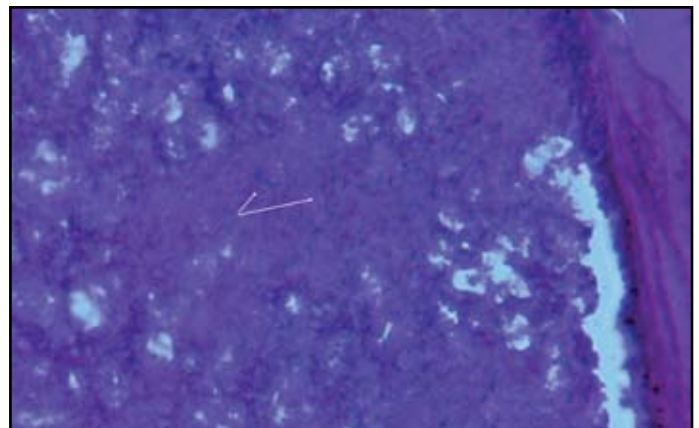
**Figure 11:** Clinical situation after removing the sequestrum on the right side in December 2006.



**Figure 12:** Sequestrum removed.



**Figure 13:** Histology showing necrotic bone, with empty lacunae and associated infected tissue. (H&E stain, magnification x 100)

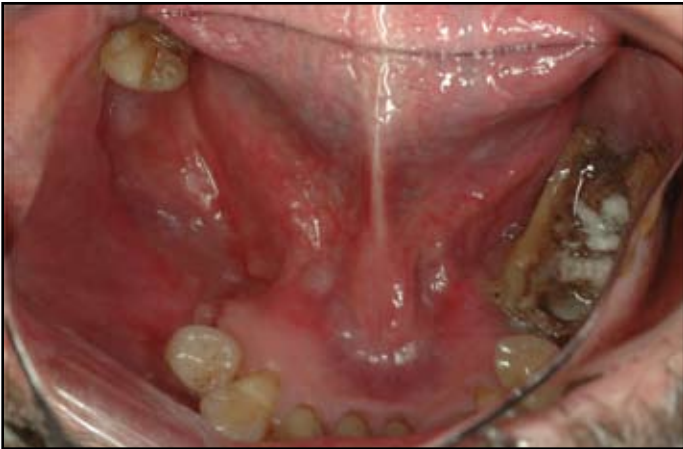


**Figure 14:** Gram staining demonstrated Gram (+) bacillus. (magnification x 100)

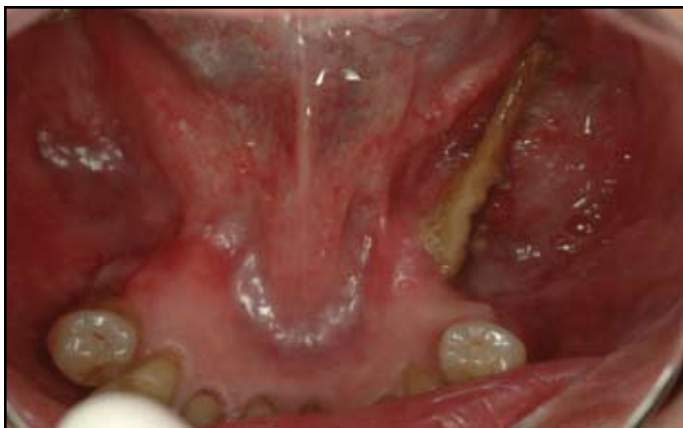week. During each visit, we carefully irrigated and cleansed the area apical to the sequestrum. To accomplish such, we used 5cc of clorhexidine 0.12% followed by 5cc of 3% hydrogen peroxide. Detritus were eliminated by means of a hand brush and finally, an additional two irrigations with clorhexidine and hydrogen peroxide were performed. After a couple of weeks the sequestrum was loose enough to attempt removal. We successfully removed the sequestrum with rongeurs and used rotary instruments to eliminate

remaining bony spicules to get a smooth bone surface and facilitate healing (figures 11,12).

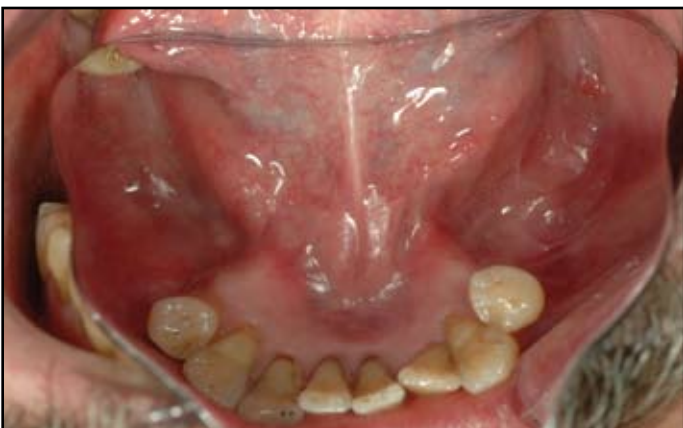The sequestrum was submitted for histologic examination which revealed necrotic bone with empty lacunae and associated infected tissue. With gram staining, Gram (+) bacillus were identified (figures 13,14). Fifteen days following surgery, the soft tissue healing looked acceptable and at one month, complete healing of the surgical site was observed (figure 15). Having achieved this, we decided



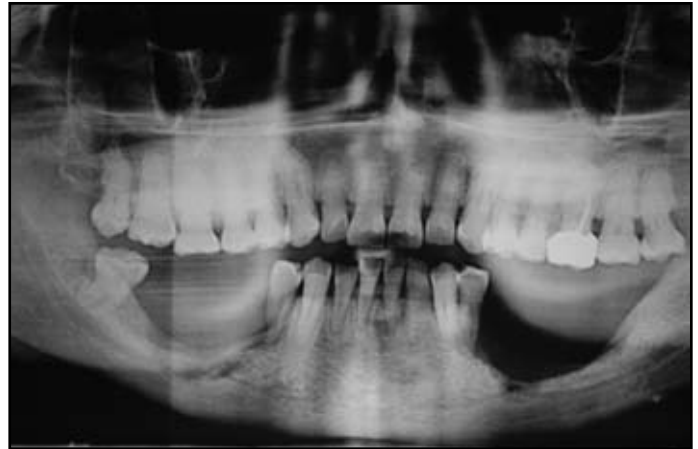**Figure 15:** Clinical situation one month after sequestrum removal.



**Figure 16:** Removal of the first part of the left sequestrum in February 2007.



**Figure 17:** Clinical situation after removal of the remaining part of the left sequestrum.



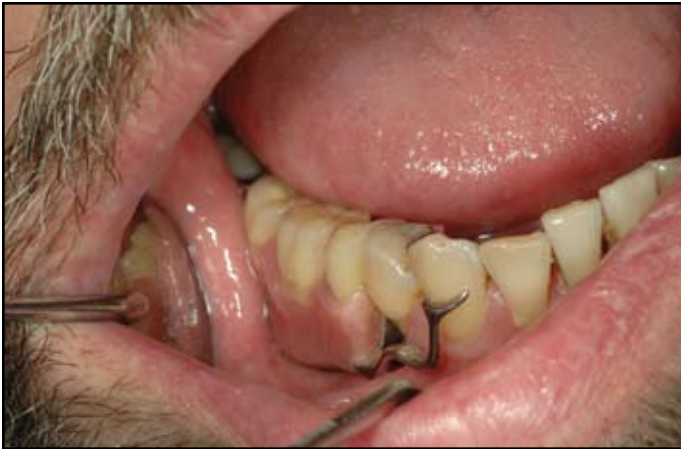**Figure 18:** Radiograph in July 2007.

to proceed in the same fashion on the left side.

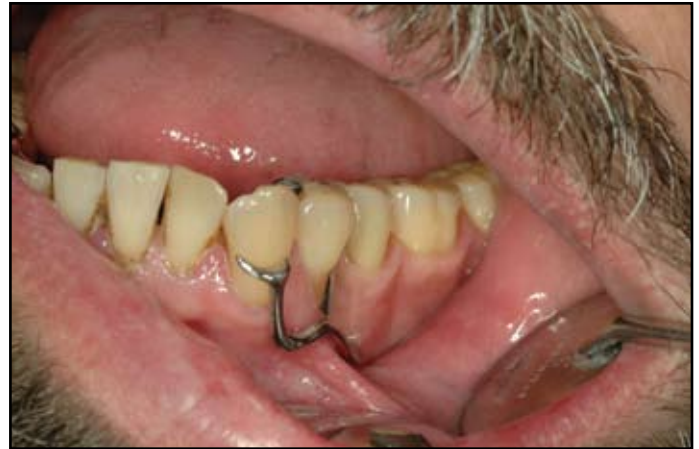Bone sequestrum on the left side presented as two parts, first from the buccal and a few months later from the lingual (figures 16,17). After two months, the tissues at the surgical sites were stable. Radiographic examination did not reveal formation of additional bone sequestrum. We also performed a Serum C-terminal telopeptide (CTX) test according to the Marx protocol<sup>8</sup> and got a result of 130 pg/ml, compatible with a moderate risk (figure 18). We then fabricated and delivered a maxillary dental prosthesis to give the patient the possibility to return to normal function, both masticatory and aesthetics wise, after several years (figures 19-21). Seventeen months later, the previously affected tissues continue to appear stable (figure 22).

## DISCUSSION

Bisphosphonate s associated osteonecrosis of the jaw was first described in late 2003 and early 2004.<sup>5,6</sup> At this time, surgery was almost totally contraindicated in these cases because of the probability of aggravating the condition. The usual recommendation was, and still applies, to main-



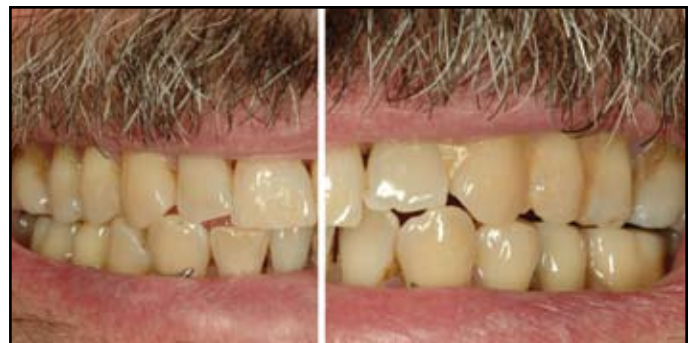**Figure 19:** Removable prosthesis.



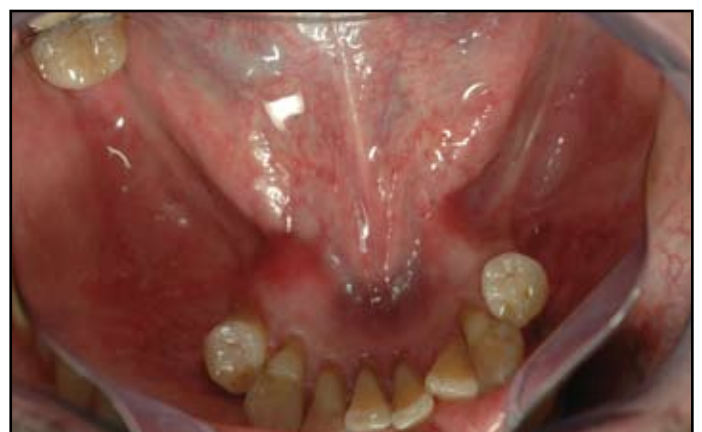**Figure 20:** Removable prosthesis.

tain the exposed bone infection free and to have in mind that the patient can live with some bone exposure without further problems.<sup>9,10</sup> However, as we demonstrated in this case, the infection of the bone can worsen, no matter how great the effort to provide minimally invasive palliative treatment.

Our thought is that once the lesion affects the cortical plate and the medullary bone becomes exposed, adequate cleansing of the area seems to be more difficult and the infection control requires extreme care, both home and professional. Chlorhexidine is the antiseptic of choice cited in most articles.<sup>9,10</sup> We also like to use 3% hydrogen peroxide based on our experience in managing abscess lesions in soft tissues which are usually present in the limits of the exposed bone. Also, 3% hydrogen peroxide can help in cases where the exposed bone presents a rough surface in which anaerobic bacteria could grow. Microbiological identification is important adjunct to aid infection management. Cultures must be made to search for aerobic and anaerobic bacteria, and also for fungus. Fungus can be present as a result of many situations, with the most common being systemic immunity impairment



**Figure 21:** Removable prosthesis.



**Figure 22:** Clinical situation in December 2008, showing stability of the soft tissues.

and the previous use of long term antibiotics.

More recently, surgical approaches have been described in order to achieve soft tissue healing in certain cases. Common features of these approaches are: 1) conservative resection of the necrotic bone with attempts at obtaining a smooth surface; 2) use of platelet derived growth factors; 3) tension free primary wound closure.<sup>11,12</sup> We have used these approaches, especially with the use of platelet derived growth factor (PDGF), both for prevention in tooth extractions in compromised patients and for treatment of BRONJ. In cases where a bony sequestrum is present, it may be beneficial to loosen them in steps rather than remove them in a single attempt. With proper homecare involving the patient irrigating below the sequestrum, this conservative approach may lead to initial healing of the overlying soft tissue, which could minimize surgical corrections upon removal of the sequestrum.

The serum C-terminal telopeptide (CTX) test<sup>8</sup> is currently recommended as a way to measure the risks of development and progression of BRONJ. When used together with imaging, clinical examination, and other complementary studies, CTX testing may prove to be a valuable adjunct in the decision process for treating patients at risk for or currently affected by BRONJ. The patient treated in this case report had moderate CTX levels and proceeded to heal without complication. Whether this healing was a result of the CTX values or the treatment rendered cannot be determined at this time.

## CONCLUSIONS

The latest literature, and also this case, supports the concept that BRONJ may be successfully treated in the short term. The approach

described to treat this case, especially regarding sequestrum management, could minimize necessary surgical corrections upon removal of the sequestrum. However, the resolution of this particular case does not ensure that every case can be resolved in the same way or with the same results, but shows us that there is a real possibility to treat this pathology with success. Each case must be evaluated individually and primary approaches must always be conservative and focused on prevention. Additional studies on the development, diagnosis, prevention, and management of BRONJ are warranted. ●

***Professional Dental Education and Professional Education Services Group are joint sponsors with The Academy of Dental Learning in providing this continuing dental education activity.***

***The Academy of Dental Learning is an ADA CERP Recognized Provider. The Academy of Dental Learning designates this activity for two hours of continuing education credits.***

***ADA CERP is a service of the American Dental Association to assist dental professionals in identifying quality providers of continuing dental education. ADA CERP does not approve or endorse individual courses or instructors, nor does it imply acceptance of credit hours by boards of dentistry.***

**Continuing Education JIACD Quiz #3**

- 1. Bisphosphonates are a class of drugs that inhibit bone resorption.**
  - a. True
  - b. False
- 2. The main use of Bisphosphonates was for the prevention and treatment of osteoporosis and other bone metabolism diseases, based on their ability to increase bone turnover through the activation of osteoclast differentiation and a decrease in its activity and survival rate.**
  - a. True
  - b. False
- 3. What percentage of BRONJ cases are associated with intravenous bisphosphonate administration?**
  - a. 2 - 10%
  - b. 1.8 - 12.8%
  - c. 12.8 - 20.3%
  - d. 0.001 - 0.002%
- 4. What is the antiseptic of choice cited for treatment?**
  - a. Saline
  - b. Listerine
  - c. Chlorhexidine
- 5. Cultures must be made to search for aerobic bacteria, anaerobic bacteria, and fungus.**
  - a. True
  - b. False
- 6. Bisphosphonate use was extended to treat oncological diseases in order to lower the skeletal effects.**
  - a. True
  - b. False
- 7. The VAD Protocol includes the use of Vincristine, Adriamycin and Dexamethasone.**
  - a. True
  - b. False
- 8. BRONJ was first described in what year?**
  - a. 2000
  - b. 1998
  - c. 2003
  - d. 2009
- 9. BRONJ must be evaluated individually and primary approaches must always be conservative and focused on prevention.**
  - a. True
  - b. False
- 10. In cases where a bony sequestrum is present, it may be beneficial to loosen them in steps rather than removing in a single attempt.**
  - a. True
  - b. False

## Disclosure

The authors report no conflicts of interest with anything mentioned in this article.

## Acknowledgements

The author (Luchetti) would like to thank Dr. Cesar Migliorati, who was kind enough to share his opinion with him in Buenos Aires regarding this particular case. The authors would also like to thank Dr. Gregori Kurtzman, Dr. Len Tolstunov, and Dr. Douglas Martin for their assistance in the preparation of this manuscript.

## References

1. Fleisch H, Russell R, Bisaz S, Casey P, Muhlbauer R. The influence of pyrophosphates analogues (diphosphonates) on the precipitation and dissolution of calcium phosphate in vivo and in vitro. *Calcif Tissue Res* 1968; 2(suppl.): 10-10a.
2. Fleisch H. Bisphosphonates: Mechanisms of action and clinical use. En: Bilezikian et al *Principles of Bone Biology*, Ed. Academic Press, 1996: 1037-1052.
3. Merlini G, Parrinello G, Piccinini L, Crema F, Fiorentini ML, et al. Long-term effects of parenteral dichloromethylene bisphosphonate (CL2MBP) on bone disease of myeloma patients treated with chemotherapy. *Hematol Oncol* 1990; 8(1):23-30.
4. Body J. Bisphosphonates for malignancy-related bone disease: current status, future developments. *Support Care Cancer* 2006; 14(5):408-418.
5. Marx R. Pamidronate (Aredia) and zoledronate (Zometa) induced avascular necrosis of the jaws: a growing epidemic. *J Oral Maxillofac Surg* 2003; 61(9):1115-1117.
6. Ruggiero S, Mehrotra B, Rosenberg T, Engroff S. Osteonecrosis of the jaws associated with the use of bisphosphonates: A review of 63 cases. *J Oral Maxillofac Surg* 2004; 62(5):527-534.
7. Mehrotra B, Ruggiero S. Bisphosphonate complications including osteonecrosis of the jaw. *Hematology Am Soc Hematol Educ Program* 2006:356-360.
8. Marx R, Cillo J, Ulloa J. Oral bisphosphonate-induced osteonecrosis: Risk factors, prediction of risk using serum CTX testing, prevention, and treatment. *J Oral Maxillofac Surg* 2007; 65(12):2397-2410.
9. Marx R, Sawatari Y, Fortin M, Broumand V. Bisphosphonate-induced exposed bone (osteonecrosis/osteopetrosis) of the jaws: Risk factors, recognition, prevention, and treatment. *J Oral Maxillofac Surg* 2005; 63(11):1567-1575.
10. Migliorati C, Casiglia J, Epstein J, Jacobsen P, Siegel M, Woo S. Managing the care of patients with bisphosphonate-associated osteonecrosis: an American Academy of Oral Medicine position paper. *J Am Dent Assoc* 2005; 136(12):1658-1668.
11. Kademani D, Koka S, Lacy M, Rajkumar S. Primary surgical therapy for osteonecrosis of the jaw secondary to bisphosphonate therapy. *Mayo Clin Proc* 2006; 81(8):1100-1103.
12. Adornato M, Morcos I, Rozanski J. The treatment of bisphosphonate-associated osteonecrosis of the jaws with bone resection and autologous platelet-derived growth factors. *J Am Dent Assoc* 2007; 138(7):971-977.